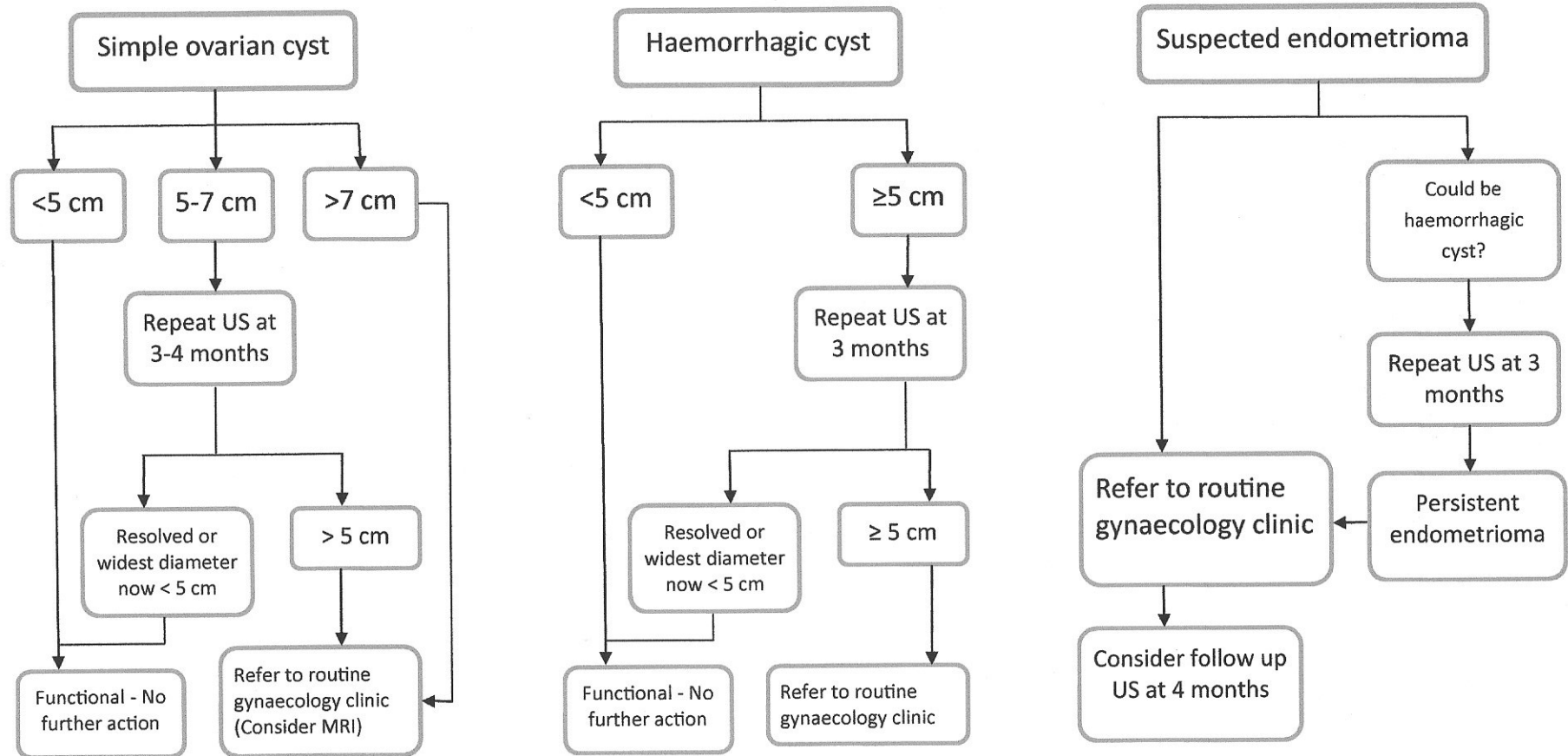
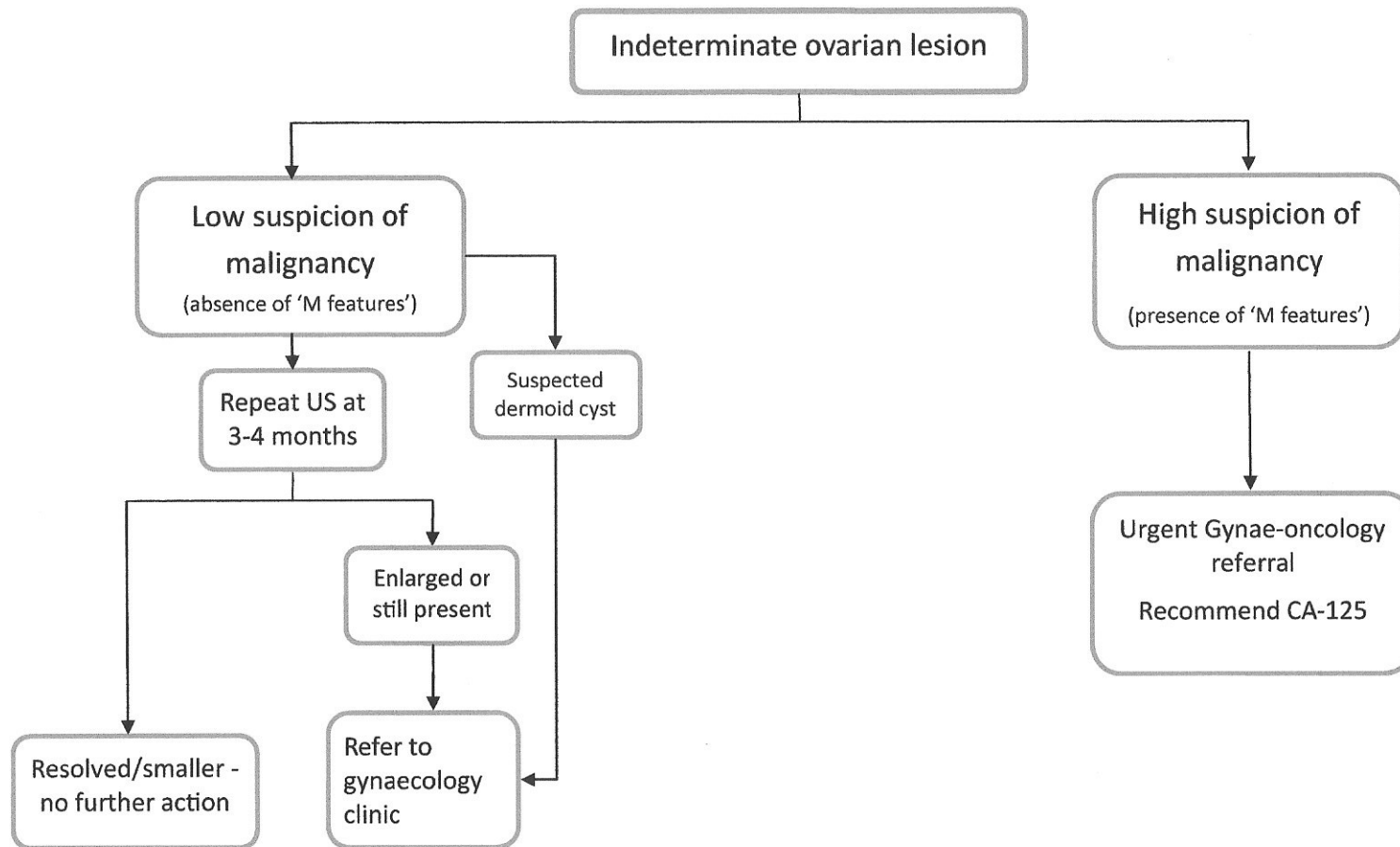


Pathways for management of pre-menopausal ovarian cysts



A simple cyst is thin walled, anechoic, with posterior acoustic enhancement and has no septation, solid component or vascularity. The following should also be treated according to simple cyst rules: a) para-ovarian cysts b) cysts containing internal daughter cysts or one thin septation measuring <3 mm c) small calcification within the cyst wall.

Pathways for management of pre-menopausal ovarian cysts



IOTA 'M features': irregular solid tumour, ascites, at least four papillary structures, irregular multilocular solid tumour with a largest diameter of at least 100 mm, high vascularity on colour Doppler examination.